

# Use of the LAHayeSIK™ Surgical System for Laser In Situ Keratomileusis

Leon C. LaHaye, MD  
 LaHaye Total Eye Care  
 Lafayette, LA

## ABSTRACT

**Purpose:** To describe a new surgical instrument and associated surgical technique to standardize the laser in situ keratomileusis surgical procedure.

**Methods:** Descriptive article providing detailed and step-by-step use of the LAHayeSIK Surgical System.

**Results:** The LAHayeSIK System provides consistent control of the surgical principles, techniques, and environment. The maintenance of an isolated surgical field, secure control of eye position, intraoperative flap management, proximal plume evacuation, even hydration, backwash-free irrigation, automated aspiration, and facilitated flap repositioning and adhesion provided by the single handpiece was found to eliminate extraneous instrumentation and improve operating efficiency while maintaining a consistently clean surgical field.

**Conclusion:** The integration of the LAHayeSIK Surgical System into a refractive practice provides in-depth and comprehensive control of basic surgical principles and techniques that are essential in significantly reducing postsurgical complications, improving outcomes, and reducing retreatments.

Laser in situ keratomileusis (LASIK) is one of the most common surgical procedures worldwide. Although the outcomes postoperatively are acceptable there are still a variety of complications that have been reported. These complications include decentrations, striae, interface debris, diffuse lamellar keratitis, infection, and central islands.<sup>1-3</sup> A variety of causes have been implicated including lack of fixation, lack of a sterile field, laser plume masking, improper handling of the flap, and the use of certain instruments during surgery.<sup>4,5</sup> Decentrations for example have been reported in excimer laser platforms that do incorporate robust eye tracking systems<sup>6</sup> Visually significant striae

can occur due to dehydration of the cornea. Additionally there have been scattered case reports of the hazardous effects of the laser plume during surgery.<sup>7</sup>

Standardization, reduced flap manipulation, and efficient plume evacuation can significantly reduce the LASIK complications outline above. We present the use of one instrument, the LAHayeSIK™ Surgical System (LAHayeSIK™) (Vision Pro LLC, Opelousas, LA, USA), with multiple functions that allows us to perform reproducible, consistently clean LASIK case after case thereby reducing surgery time, reducing complications, improving outcomes, and minimizing risk.

The LAHayeSIK™ handpiece is a precision-made, one-handed instrument that provides multiple functions including surgical field downsizing and isolation, globe fixation, hemostasis control, keratotomy flap control, at-the-site smoke evacuation, target tissue hydration management, contained irrigation and fluid aspiration, flap repositioning, and accelerated flap adherence.

The LAHayeSIK™ handpiece is placed on the eye following Stage I (keratotomy) prior to reflecting the flap and remains on the eye until the procedure has been completed. The LAHayeSIK™ Surgical System provides the surgeon with exquisite, total control of the LASIK surgical procedure throughout Stage II (incision exposure to incision closure).

The integration of LAHayeSIK™ into a refractive practice is enjoyable and introduces new enthusiasm for the LASIK procedure, but does have a learning curve. The conversion is akin to phaco-emulsification. Once past the learning curve, this author believes the surgical procedure is actually easier and more efficient than the conventional LASIK surgical technique.

The depth and comprehensiveness of the LAHayeSIK™ System complements basic surgical principles and standardizes surgical regimes. LASIK with LAHayeSIK™ requires significantly fewer instruments and reduced flap manipulations while providing greater control of the entire surgical procedure by employing the following:

1. Precise control of eye movements during ablation allowing for enhanced accuracy and efficacy of ablation

Address correspondence and reprint requests to: Leon C. LaHaye, LaHaye Total Eye Care, 201 Rue Iberville, Ste. 800, Lafayette, LA (e-mail: ifxiis@lahayesight.com).

2. Reduced patient anxiety from eliminating their responsibility to fixate
3. Stromal bed and flap protection from contamination, the maintenance of clean surgical field
4. Avoidance of unwanted hydration of target tissue and its negative impact on laser effectiveness
5. Efficient, laminar low-flow proximal plume evacuation maximizing laser effectiveness and removal of noxious fumes and potentially hazardous particles
6. “No-touch” reproducibility of target stromal dehydration; minimization of excessive manipulation of bleeding vessels at bed margins
7. On-demand “backwash-free” sterile irrigation and aspiration
8. Facilitation of flap repositioning and accelerated flap adhesion with minimal manipulation.


Once mastered, the LAHAYESIK™ Surgical System allows for a reproducible, consistently clean LASIK procedure with improved efficiency and reduced surgery time.

## ■ LAHAYESIK™ SURGICAL TECHNIQUE

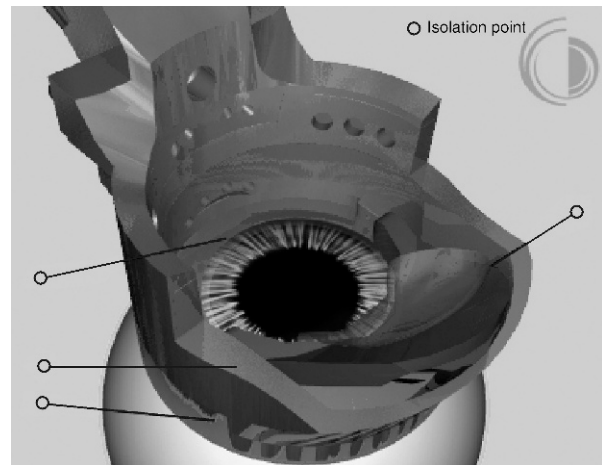
Below we outline the LAHAYESIK™ surgical technique in the order that it is used.

### ■ EYE FIXATION

Surgeon-controlled fixation allows for precise control of eye movements during ablation helping to ensure accurate treatment of cylinder axis and wavefront-guided ablations, while reducing complete dependence on complex, sensitive eye tracker systems. The use of



**FIGURE 1.** Globe fixation using the LAHAYESIK™ instrument.



**FIGURE 2.** Surgical field containment using the LAHAYESIK™ instrument.


this fixation feature of LAHAYESIK™ complements the track mechanism by fixing the globe in place to ensure accurate laser delivery.<sup>9</sup>

Prior to performing the keratotomy the author recommends placement of centered radial marks on the cornea that are in “true alignment” (on axis) with the 3, 6, 9, and 12 o’clock positions. This is easily done utilizing an “old” RK marker. Meticulous attention in noting the position of the first and third Purkinje images when the patient initially fixates prior to making the flap and again prior to placement of the LAHAYESIK™ handpiece on the eye is essential. Preoperative constriction of the pupil will further improve precision. This author’s preferred technique is to align on the visual axis for laser delivery.

After completion of the keratotomy and prior to reflecting the flap, the surgeon places the LAHAYESIK™ handpiece on the eye so that the forward edge of the platform is parallel to the flap hinge and the limbus is centered within the lower ring of the handpiece. Once positioned, the handpiece must be held in position with moderate pressure and must not be lifted until the end of the procedure.

The conformed fit of the LAHAYESIK™ footplate to the globe provides gentle, atraumatic eye fixation relative to the handpiece (Fig. 1).

Surgeon-controlled fixation provided by LAHAYESIK™ provides the ability to precisely center, fixate, and account for any rotational movements relative to the aiming beam and reticule of the laser. Proper positioning of the eye is maintained to ensure the target stroma/iris plane is perpendicular to the laser beam. This is achieved by ensuring that the aiming beam is centered on the visual axis, and the 3, 6, 9, and 12 o’clock cross hairs of the aiming reticule are superimposed over



**FIGURE 3.** Hemostatic control by applying constant circumferential limbal pressure.

the corresponding limbal marks placed by the RK marker. This technique assures exact beam placement and patient anxieties are reduced by eliminating their responsibility to fixate. The LAHayeSIK™ Surgical System does not interfere with laser eye tracking systems infrared or laser radar eye tracking systems.

### ■ SURGICAL FIELD DOWNSIZING AND CONTAINMENT

LAHayeSIK™ handpiece creates a wall of containment around the ablation area to prevent inadvertent contact with the conjunctiva, lid margins, surgical drapes, and irrigation backwash. Unwanted hydration of the stroma and its negative impact on laser effectiveness is avoided and the stromal bed is protected from contamination. Effective containment is one reason that, once placed, the handpiece must not be lifted until the end of the surgical procedure (Fig. 2).

### ■ HEMOSTASIS CONTROL


With the creation of larger corneal flaps and treatment zones, limbal ciliary vessels may be cut during the keratotomy. The resulting bleeding can cause a delay of the procedure and other complications that may affect outcome. The lower ring of the LAHayeSIK™'s handpiece is designed to allow the application of 360° of pressure on the limbal vessels to facilitate hemostasis (Fig. 3).

When bleeding is noted the surgeon applies sustained pressure with the handpiece. LAHayeSIK™ conformed pressure and contained delivery of chilled BSS irrigation/aspiration helps keep the area clean, free of blood, and ready for flap reflection, ablation, and replacement.

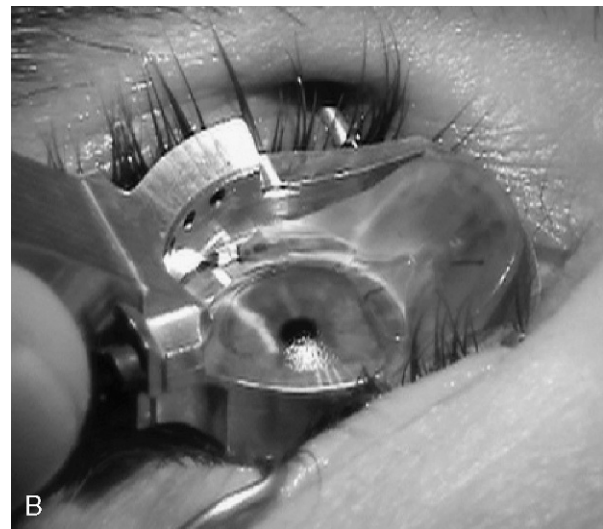
### ■ KERATOTOMY FLAP CONTROL

Reducing manipulation of the corneal flap and stroma may decrease some postoperative complications.<sup>10,11</sup> The LAHayeSIK™ handpiece provides a hinged platform to support and protect the corneal flap during ablation (Fig. 4).

Placement of the flap onto the LAHayeSIK™ platform is easily and quickly accomplished by placing the middle of the smooth rounded spatula end to the outside edge of the flap/bed opposite end from the hinge, applying a moderate amount of downward pressure while sliding under the flap across the stromal bed to the hinge, onto the platform. Surface tension holds the flap in position elevated and protected from adsorbing cul-de-sac fluids and excessive hydration.



A



B

**FIGURE 4.** (A and B) Proper placement of flap on hinged platform.




FIGURE 5. Delivery of laminar airflow.

## ■ TARGET TISSUE HYDRATION MANAGEMENT

Research suggests the importance of developing surgical techniques that ensure equal, reproducible stromal dehydration from case to case.<sup>5,12</sup> Unavoidable hydration variations of the target stroma occur as a consequence of direct introduction of fluid into the interface during the keratotomy and flap reflection. Intra-ablation hydration variability occurs from direct release of water from cellular disruption and precipitation of plume water vapor onto the stromal surface. Stromal surface fluid directly masks the effectiveness of the laser contributing to less than desired outcomes including central islands, under corrections, and higher-order aberrations. A reflective stroma indicates fluid accumulation.

The LAHayeSIK™ System delivers filtered laminar airflow to evaporate excessive moisture from the stromal bed before and during ablation allowing for equal stromal hydration from patient to patient (Fig. 5).

Non-turbulent, uniform sterile air delivery is controlled by the surgeon by means of a footswitch helping to ensure consistent results. A homogeneously dull appearance of the target stroma indicates the desired state to maintain throughout ablation.

Variable factors will determine the frequency and duration of use of this feature including surgeon technique, laser used, and OR room air density.

The author finds maximum benefit of this feature is achieved by use prior to beginning ablation and again multiple times throughout ablation to “re-establish” that desired homogeneously dull state. Initial users frequently under-use this important feature.

## ■ AT-THE-SITE PLUME EVACUATION

LAHayeSIK™ seven-port laminar flow smoke evacuation system removes LASIK smoke and water vapor just millimeters from the ablated surface (Fig. 6) (data on file at Vision Pro., LLC).

Surgical smoke is quickly removed from the laser beam path to reduce masking that can cause under-corrections, irregular astigmatism, and central islands.<sup>2</sup>

Research confirms that smoke removal systems with vacuum ports placed inches away from the ablation site are largely ineffective.<sup>13</sup>

The close proximity of LAHayeSIK™ evacuation ports to the ablating surface allows immediate removal of smoke as it is formed, clearing the way for the next laser pulse and reducing exposure to potentially toxic smoke plume particles.

Efficient smoke removal decreases deposition of smoke particles on the laser’s exposed optics, reducing the need for cleaning or replacement. Additionally concerns have been raised of the hazardous health effects of the laser plume, the so-called “laser lung”. Recent evidence suggests that polypeptides can potentially be aspirated by health care personnel near the laser and become embedded in lungs.

Depression of the plume-smoke evacuation foot control activates the plume evacuation pump and the preemptive fluid aspiration. This footswitch is placed for use by either the physician or assistant. The laminar flow plume evacuation flow rate can be adjusted, with the Plume Evacuation Control Knob located on the front of the cart near the Master Switch, from 0 to 30 L/min.

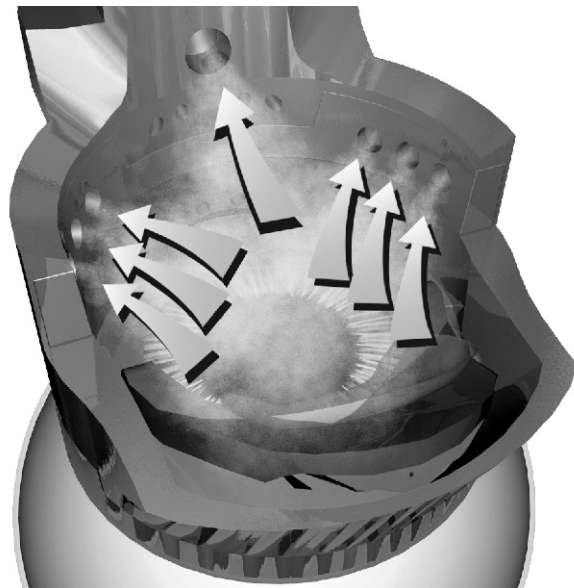
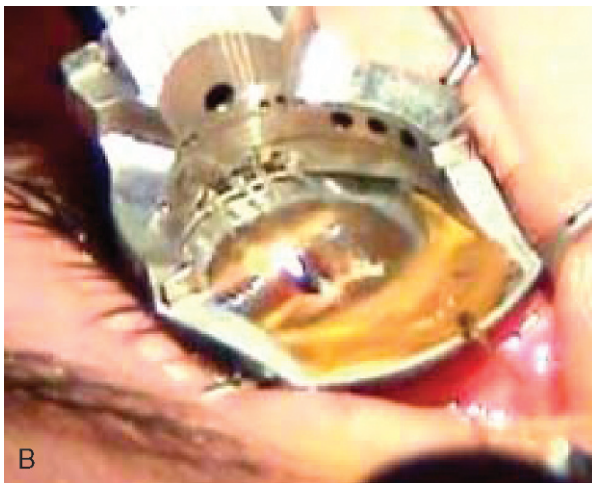
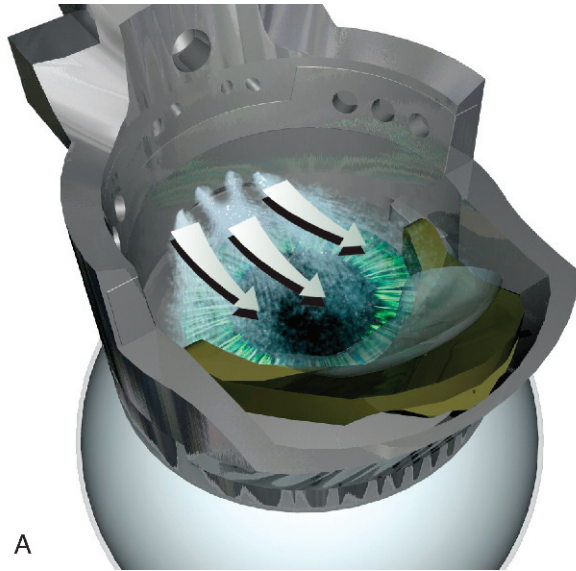


FIGURE 6. Plume evacuation function of the LAHayeSIK™ instrument.



**FIGURE 7.** (A and B) Sterile irrigation of the surgical field.

The author recommends activating LAHayeSIK™ plume evacuation pump just prior to initially reflecting the flap onto the platform. This will maximize the preemptive aspiration feature removing unwanted fluid from the surgical field prior to flap reflection.

The surgeon proceeds with the technique described, in the section **FIXATION**, to assure laser alignment with or without tracking. After completion of the ablation, turn off the plume evacuation function.

### ■ A HELPING HAND WITH IRRIGATION, ASPIRATION, AND FLAP REPOSITIONING

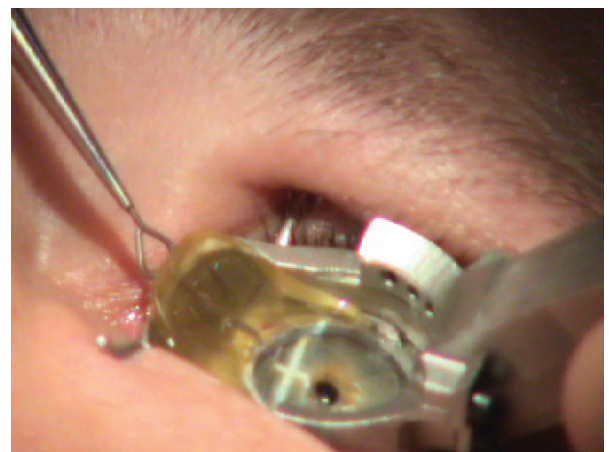
Standard flap repositioning consists of a series of steps and manipulations that predispose the operation to complications. Irrigation can create pools that backwash

into the surgical field and increase risk of contamination and excessive manipulations of the corneal flap and stromal bed increase postoperative complications. The LAHayeSIK™ Surgical System offers the means to ensure the cleanest, most efficient means of flap repositioning, minimizing manipulations and preventing backwash contamination.

Sterile irrigation and aspiration (I/A) are delivered via a foot-controlled pedal to cleanse and re-hydrate the corneal bed easily and consistently prior to flap repositioning without concern for backwash (Fig. 7). In addition to providing a place to temporarily support and protect the flap during ablation the platform facilitates repositioning of the flap with minimal manipulation; globe fixation and surgical field containment is simultaneously maintained.

Returning the flap to exact apposition via LAHayeSIK™ technique is effortless, but does require proper timing of I/A and platform utilization.

1. Prior to I/A it is essential that the platform is engaged with the flap repositioning end of the LAHayeSIK™ Flap Instrument at the designated groove located on the platform (Fig. 8).
2. It is recommended that maximum or near-maximum irrigation be delivered quickly by fully depressing the pedal for 1 to 2 seconds. This is usually sufficient to thoroughly rinse and re-hydrate the flap and flap bed in preparation for repositioning.
3. Following the 1 to 2 second irrigation/aspiration release the IA foot pedal and without delay move the platform on a controlled course remaining perpendicular to the hinge. The corneal flap will be observed sliding from the platform and onto the stromal bed (Fig. 9). With little practice LAHayeSIK™ allows



**FIGURE 8.** The apposition of the LAHayeSIK™ Flap instrument into the flap platform to enable flap reflection.

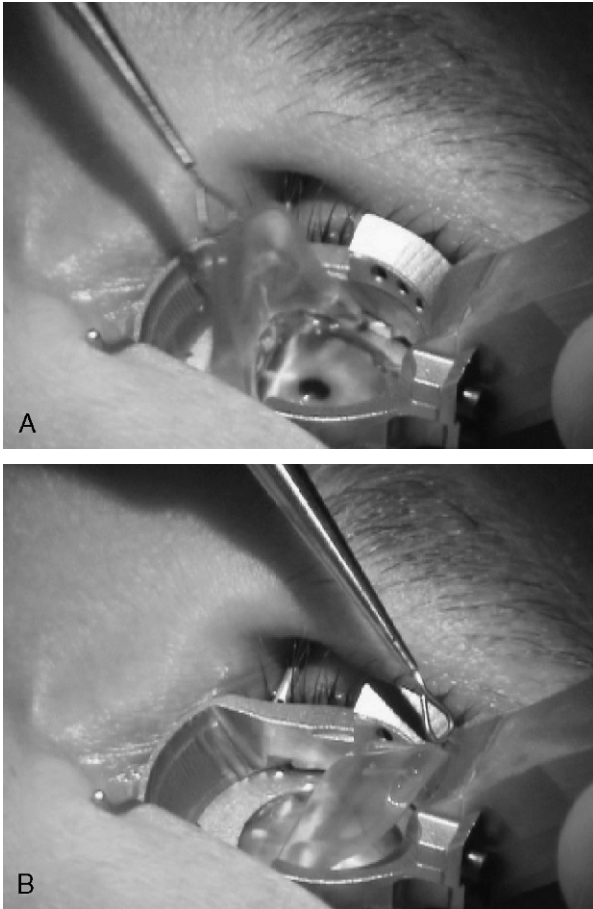


FIGURE 9. (A and B) Proper flap reflection technique.

for exact flap repositioning with minimal manipulation while protecting against backwash.

4. Flap adhesion is accelerated by uniform evaporation of excessive moisture utilizing the sterile aeration feature of LAHAYESIK™ (Fig. 5).

Because LAHAYESIK™ flap repositioning/adherence is so quick (10–15 seconds), it is common for initial users to overly manipulate and squeeze the flap—a difficult habit to stop.

Excessive use of the sterile air delivery feature will cause the flap to shrink. This is evident from a widening of the gutter. Applying gentle I/A or “smoothing” with a moistened micro-sponge will reverse excessive dryness of the flap.

The LAHAYESIK™ handpiece is removed after verification of flap alignment and adherence thereby completing the procedure.

If it is noted that the flap is not perfectly aligned following platform use, the flap repositioning instrument end or a moistened micro surgical sponge can be

used to provide minor manipulation to facilitate exact alignment. It is imperative to perform this step without delay. Each of the radial marks will assure that each quadrant is in exact alignment. If the flap is grossly misaligned, it is preferable to re-reflect the flap onto the platform and repeat the repositioning technique beginning at *a*. It is important to maintain the LAHAYESIK™ handpiece positioned on the globe until flap adherence so that maximum surgical field containment is provided.

Some of the common reasons that beginners experience less than perfect replacement using LAHAYESIK™ include:

- Continuing irrigation during platform (and flap) reflection. This may result in the flap prematurely sliding from the platform in between the arms of the platform. If this does occur the handpiece is kept in place to maintain isolation and the flap replacement instrument is used to nudge the flap into alignment. Returning the platform to the start position allows complete access to the contained surgical field making this maneuver much simpler.
- Prolonging the time between irrigation and platform flipping. This may result in the flap not completely sliding from the platform. If the flap end is still “hanging” on the platform after flipping over the flap repositioning end of the flap instrument can be used to gently nudge the flap free. Returning the platform to the start position will allow more access making fine repositioning easier.

## ■ DISCUSSION

The standardization of any surgical procedure is imperative to maximize clinical outcomes. In the case of LASIK, standardization can potentially obviate a variety of complications and potential health concerns for patient and surgeon alike. By using a handpiece that isolates the surgical field, a more sterile procedure is possible. Reducing the number of instruments used (especially surgical sponges) can potentially decrease the incidence of epithelial ingrowth and diffuse lamellar keratitis and the protracted postoperative treatments. The use of an instrument that enables the surgeon to fixate the globe decreases the chances of decentered ablations regardless of an excimer system that employs an eyetracker.<sup>8,14</sup> Additionally the eye undergoes minute tilts and torsion throughout the ablation that may be too rapid for an eye tracker to compensate or the compensation may not occur in a timely manner. In either case the laser ablation may not be perpendicular to the cornea creating an angle of incidence that under ablates the cornea or creates irregular astigmatism. The use of titrated amounts of aspiration and irrigation in

sterile manner allows reduced flap manipulation and the potential for visually significant striae.

The author has performed over 200 LASIK procedures with LAHayeSIK™ using a Nidek EC5000 without tracking. Prior surgical experience includes 15 years experience with lamellar refractive procedures since first introducing ALK onto the North American Continent.

After attaining proficiency with the LAHayeSIK™ Surgical System immediate benefits were realized. The ability to perform 9 to 10 LASIK procedures per hour with the level of standardization, strict adherence to surgical protocol, and consistency is allowing me to fine tune my personal nomograms resulting in the attainment of quality outcomes. Bottom line—In addition to intra-operative efficiency and enjoyment, post operatively my enhancement rate is less than 1%, without occurrence of epithelial ingrowth, diffuse lamellar keratitis, or infectious keratitis. All of the interfaces are pristine. At 3 months 89% of patients are within  $\pm 0.25$  diopters of intended refraction and 98% within  $\pm 0.50$  of intended correction. To return to performing LASIK without LAHaye would be unfair to my patients and me.

## ■ REFERENCES

1. Stulting RD, Carr JD, Thompson KP, et al. Complications of laser in situ keratomileusis for the correction of myopia. *Ophthalmology*. 1999;106:13–20.
2. Cua IY, Prepose JS. Proper positioning of the plume evacuator in the VISX Star S3 excimer laser minimizes central island formation in patients undergoing Laser in situ keratomileusis. *J Refract Surg*. 2003;19(3):309–315.
3. Jin GJ, Lyle WA, Merkley KH. Late-onset idiopathic diffuse lamellar keratitis after laser in situ keratomileusis. *J Cataract Refract Surg*. 2005;31:435–437.
4. Blustein JN, Hitchins VM, Woo EK. Diffuse lamellar keratitis, endotoxin, and ophthalmic sponges. *J Cataract Refract Surg*. 2004;30:2027–2028.
5. Dougherty PJ, Wellish KL, Maloney RK. Excimer laser ablation rate and corneal hydration. *Am J Ophthalmol*. 1994;118:169–176.
6. Fiore T, Carones F, Brancato R. Broad beam vs. flying spot excimer laser: refractive and videokeratographic outcomes of two different ablation profiles after photorefractive keratectomy. *J Refract Surg*. 2001;17:534–541.
7. Taravella MJ, Viega J, Luiszer F, et al. Respirable particles in the excimer laser plume. *J Cataract Refract Surg*. 2001;27:604–607.
8. Bueeler B, Mrochen M. Simulation of eye-tracker latency. Spot size, and ablation pulse depth on the correction of higher order wavefront aberrations with scanning spot laser systems. *J Refract Surg*. 2005;21:28–36.
9. Lipshitz I. Thirty four challenges to meet before excimer laser technology can achieve super vision. *J Refract Surg*. 2002;18:740–743.
10. Pushker N, Dada T, Sony P, et al. Microbial keratitis after laser in situ keratomileusis. *J Refract Surg*. 2002;18:280–286.
11. Belda J, Artola A, Alio J. Diffuse lamellar keratitis 6 months after uneventful laser in situ keratomileusis. *J Refract Surg*. 2003;19:70–71.
12. Oshika T, Klyce SD, Smolek MK, et al. Corneal hydration and central islands after excimer laser photorefractive keratectomy. *J Cataract Refract Surg*. 1998;14:1575–1580.
13. Dell S. New system permits safe, more effective plume evacuation. *Ophthalmology Times*. April 15, 2003.
14. Coopender SJ, Klyce SD, McDonald MB, et al. Corneal topography of small-beam tracking excimer laser photorefractive keratectomy. *J Cataract Refract Surg*. 1999;25:674–684.